Scand J Work Environ Health 12 (1986) 277—279

Vibration exposure — A modifier of the onset of amyloid polyneuropathy

A case report

by Mats Hagberg, MD, PhD,[1] Bela Almay, MD,[2] Birgitta Kolmodin-Hedman, MD, PhD,[1] Bo Zetterlund, MD[3]

HAGBERG M, ALMAY B, KOLMODIN-HEDMAN B, ZETTERLUND B. Vibration exposure — A modifier of the onset of amyloid polyneuropathy: A case report. *Scand J Work Environ Health* 12 (1986) 277—279. In 1979 a 60-year-old male electrician exposed to vibration from a hand-held hammer-drill an hour a day for 22 years noted numbness in fingers II—IV on both hands. The symptoms increased over a period of three years. Electromyography revealed carpal tunnel syndrome. During 1982 the patient noticed numbness, not only in his hands, but also in his arms. The sensory disturbances in his arms were neither uniformly nor segmentally distributed but appeared to follow single nerves and thus indicated polyneuropathy. A rectal biopsy showed amyloid deposits. Since there was no detectable cause for the amyloid disease, it was regarded as primary amyloidosis. The exposure to hand-arm vibration was regarded as a factor modifying the onset and possibly also the severity of symptoms in the hands. The social insurance authorities agreed to pay half the accepted workmen's compensation to the patient for the initial two years of sick leave from work. After the two years the disease itself was regarded as being "responsible" for all symptoms.

Key terms: amyloidosis, carpal tunnel syndrome, occupational diseases, paresthesia, vibration, workmen's compensation.

In recent years there has been increased interest in the neurological effects of hand-arm vibration. Carpal tunnel syndrome, as well as nonspecific neurological disturbances such as numbness and paresthesia, have been linked to exposure to hand-arm vibration (4, 5, 9). Juntunen & co-workers have suggested that patients with neuropathic diatheses tend to be selected into groups of patients with suspected vibration syndrome (10). The aim of this presentation is to illustrate the interrelationships between systemic disease and vibration exposure by means of a case history and, furthermore, to interpret this interrelationship in view of workmen's compensation.

Case history

A 60-year-old male electrician noted numbness in fingers II—IV on both hands in 1979. The symptoms increased over a period of three years and ascended in a proximal direction from the fingertips to involve/affect the whole finger in 1982. He had no symptoms from the lower extremities. The patient had difficulty continuing to work since he became clumsy and often dropped tools and materials. Because of the sensory disturbances the patient was referred by an industrial physician as a suspected case of vibration-induced neuropathy to the neurological clinic.

The occupational history revealed that the patient had been exposed to hand-arm vibration from a hammer drill used for approximately 1 h a day for 22 years. The critical opening pressure of the digital arteries was reduced at low temperatures and therefore indicated vasoconstriction (5).

Electromyography revealed bilateral denervation of the thenar muscles. The distal motor latencies were increased in the median nerve, and no sensory potentials could be recorded. These findings, together with the patient's symptoms, indicated carpal tunnel syndrome. The surgeon reported "pressure marks" on both median nerves when the carpal ligament was cut for decompression, but the patient did not recover from any of the symptoms.

During 1982 the patient's symptoms increased. He then suffered numbness, not only in his hands, but also in his arms. In 1983 the patient also developed symptoms of numbness and sensory disturbances in the lower extremities and experienced difficulties in walking. An additional electromyographic examination revealed distal polyneuropathy of the axonal type. The routine neurological investigation to exclude major causes of polyneuropathy such as vitamin deficiency, alcohol, diabetes, uremia, etc, was negative. Finally a rectal biopsy showed amyloid deposits. There were neither hereditary factors nor secondary causes (eg, rheumatoid arthritis) to explain the amyloidosis. Hence

[1] National Board of Occupational Safety and Health, Medical Division, and the Department of Occupational Medicine, University Hospital, Umeå, Sweden.
[2] Department of Neurology, University Hospital, Umeå, Sweden.
[3] Department of Clinical Neurophysiology, University of Umeå, Umeå, Sweden.

Reprint requests to: Dr M Hagberg, NBOSH, Medical Division, Box 6104, S-900 06 Umeå, Sweden.

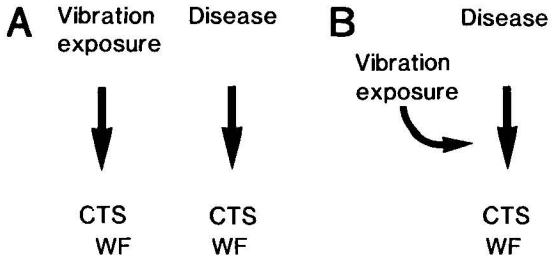

Figure 1. Both exposure to hand-arm vibration and primary amyloidosis can cause carpal tunnel syndrome (CTS) and white finger (WF) (A). It is possible that exposure to hand-arm vibration modifies amyloid disease by initiating the onset of symptoms of amyloid disease sooner and localizing them to the upper extremities (B).

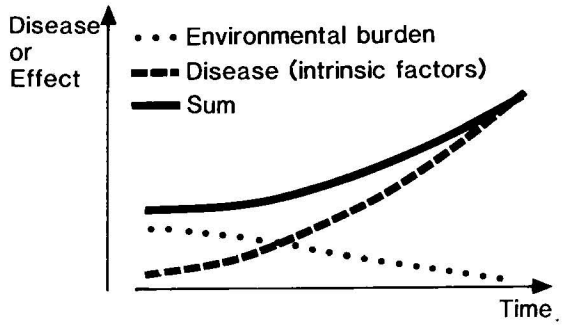

Figure 2. At the onset of symptoms (disease/effect) the major cause was probably the exposure to hand-arm vibration (environmental burden); the minor contribution from the amyloidosis could have made the symptoms clinical, ie, difficulties in working. As time passed the amyloidosis progressed to become the major cause of symptoms (effect).

the diagnosis was "primary amyloidosis with polyneuropathy (sporadic case)."

Discussion

Interrelationships between systemic disease and vibration

Primary amyloidosis with polyneuropathy is caused by amyloid deposits in nervous tissue (7). In Sweden primary amyloidosis with polyneuropathy of both the sporadic and familial type is described as starting distally in the lower extremities with the involvement of the upper extremities at a later stage in the disease (3).

It is possible that the exposure to hand-arm vibration caused both the carpal tunnel syndrome and the vasoconstriction of the digital arteries at low temperature (figure 1) (5, 8). On the other hand, it is also possible that the disease (amyloidosis) caused both the carpal tunnel syndrome and vasoconstriction at a low temperature (figure 1) (2, 3). However, the most likely explanation is that both the disease and the exposure produced the patients' symptoms. Thus exposure to hand-arm vibration may either have influenced the location of amyloid deposits or influenced the effects of such deposits. The location of amyloid deposits in nervous tissue is described in Swedish studies as affecting the lower extremities (1). However, the incidence of carpal tunnel syndrome in primary amyloidosis has also been described as ranging between 13—27 % (6). Another theory is that the effects of the amyloid deposits were aggravated by the exposure to hand-arm vibration.

The present case illustrates the importance of extended neurological and neurophysiological examination when vibration-induced localized neuropathy is being considered in a patient.

Workmen's compensation

The exposure to hand-arm vibration could have *caused* the initial symptoms in the patient. However, it is more probable that the exposure to hand-arm vibration either *aggravated* the amyloid disease or *accelerated* the progress and localized the disease to the upper extremities. The social insurance authorities agreed to our suggestion that they pay one-half of the workmen's compensation for the initial two years of sick leave from work. After two years the disease — primary amyloidoses with polyneuropathy — was regarded as being responsible for all symptoms. One could argue that during the initial two years, when the patient's symptoms rapidly became aggravated and also started to involve the lower extremities, that the disease was taking over the responsibility for all symptoms (figure 2). We regarded the exposure to vibration as a modifier of the onset of the amyloid polyneuropathy by aggravating the symptoms or by localizing the symptoms to the upper extremities.

References

1. Andersson R, Blom S. Neurophysiological studies in heredity amyloidosis with polyneuropathy. Acta Med Scand 191 (1972) 233—239.
2. Bjerrum OW, Rygaard-Olsen C, Dahlerup B, Bang FB, Haase J, Jantzen E, Overgaard J, Sehested P. The carpal tunnel syndrome and amyloidosis. Clin Neurol Neurosurg 86 (1984) 29—32.
3. Blom S, Steen L, Zetterlund B. Familial amyloidosis with polyneuropathy — Type 1. Acta Neurol Scand 63 (1981) 29—32.
4. Bovenzi M, Petronio L, DiMarino F. Epidemiological survey of shipyard workers exposed to hand-arm vibration. Int Arch Occup Environ Health 46 (1980) 251—266.
5. Cannon LJ, Bernachi EJ, Walter SD. Personal and occupational factors associated with carpal tunnel syndrome. J Occup Med 23 (1981) 255—258.
6. Chapman RH, Cotter F. The carpal tunnel syndrome and amyloidosis. Clin Orthop Related Res 169 (1982) 159—162.
7. Cohen AS, Rubinow A. Amyloid neuropathy. In: Dyck PJ, Thomas PK, Lambert EH, Bunge R, ed. Peripheral neuropathy. WB Saunders, Philadelphia, PA 1984, pp 1866—1898.
8. Ekenvall L, Lindblad LE. Digital blood pressure after local cooling as a diagnostic tool in traumatic vasospastic

disease. Br J Ind Med 39 (1982) 388—391.
9. Hagberg M, Johansson R, Zetterlund B. Tactile perception in workers with vibration syndrome. In: Abstracts to fourth international symposium on hand-arm vibration, Helsinki May 6—8, 1985. Helsinki 1985, p 56.
10. Juntunen J, Matikainen E, Seppäläinen AM, Laine A. Peripheral neuropathy and vibration syndrome. Int Arch Occup Environ Health 52 (1983) 17—24.